



## ***In vivo* Effect of Cassava Flakes Mixed with *Euphorbia heterophylla* against *Salmonella typhi***

F. O. Omoya<sup>1\*</sup>, A. O. Momoh<sup>1</sup> and O. A. Olaifa<sup>1</sup>

<sup>1</sup>Department of Microbiology, Federal University of Technology, PMB 704, Akure, Ondo State, Nigeria.

### **Authors' contributions**

This work was carried out in collaboration between all authors. Author FOO designed the study and experimental protocol, Authors AOM and OAO performed the experiments, managed the literature searches and analyses of the study. Authors FOO and AOM wrote the first draft of the manuscript and critically revised the manuscript. All authors read and approved the final manuscript.

### **Article Information**

DOI: 10.9734/EJMP/2015/8979

Editor(s):

(1)

(2)

Reviewers:

(1)

(2)

(3)

(4)

Complete Peer review History:

Original Research Article

Received 9<sup>th</sup> January 2014  
Accepted 19<sup>th</sup> September 2014  
Published 16<sup>th</sup> February 2015

### **ABSTRACT**

**Aims:** The therapeutic effect of *Euphorbia heterophylla* and cassava flakes mixture in treatment of Salmonellosis was studied *in vivo*.

**Methodology:** Antibacterial activity of aqueous extract of *Euphorbia heterophylla* was first evaluated using agar well diffusion method by measuring the diameters of zones of inhibition on *Salmonella typhi* *in vitro*. The test organism was susceptible to *Euphorbia heterophylla* extract. Albino rats were infected with *Salmonella typhi* and confirmed using WIDAL test.

**Results:** The result showed that the infectivity dose was  $2.0 \times 10^2$  cfu/ml for an albino rat of average weight 110 g. The qualitative analysis of the phytochemical of the plant showed that anthraquinone, glycosides and alkaloid are present. The analysis of the pH of the white cassava flakes used was 3.83 while that of the red cassava flakes was 5.62. The titre value of the infected rats increased significantly from 1:20 to 1:160 three days after infection. Administration of *Euphorbia heterophylla* with cassava flakes mixture was found to effectively treat and reduce the titre value to 1:20 after treating for 7 days. The infection caused a decreasing effect on the haematological parameters

\*Corresponding author: Email: fomoya@yahoo.com;

such as PCV and WBC. The histopathological analyses of the organs of the infected rats caused mild to severe pathological changes varying from widespread vascular damage, haemorrhage, vasculitis, cellular degeneration and necrosis of the organs. The therapeutic effect of the treatment administered using the *Euphorbia heterophylla* – cassava flakes mixture showed recuperating cells of the organs analysed histopathologically.

**Conclusion:** The results obtained in this work showed that *Euphorbia heterophylla* mixed with cassava flakes is an effective therapeutic agent for Salmonellosis and that the *Euphorbia heterophylla* with white cassava flakes mixture is more effective in the treatment of Salmonellosis.

**Keywords:** Cassava flakes; *Euphorbia heterophylla*; *Salmonella typhi*; therapeutic.

## 1. INTRODUCTION

*Salmonella* is a member of the family *Enterobacteriaceae* [1]. *Salmonella* spp. causes wide range of diseases such as enteric fever, gastroenteritis and bacteraemia. *Salmonella* is a leading cause of food borne illness [2,3]. Food borne infections caused by *Salmonella* serotypes occurs at high frequency in industrialized nations and developing countries and is an important public health problem worldwide. Salmonellosis is a common disease caused by numerous *Salmonella* serovars with clinical manifestations that vary from severe enteric fever to mild food poisoning [4] both in animals [5] and humans [6]. It is characterized by diarrhoea, headache, abdominal pain, fever, and vomiting, beginning 6 to 72 hours after infection. There are many different kinds of these bacteria causing salmonellosis in which *Salmonella* serotype Typhimurium and *Salmonella* serotype Enteritidis are the most common types [7].

*Euphorbia heterophylla* is an important medicinal herb, belongs to the family *Euphorbiaceae* that has been widely used in traditional medicine in various parts of Africa [8,9] including Nigeria. *E. heterophylla* has been used for the treatment of constipation, bronchitis and asthma. The plant has also been used as purgative [10,11]. The desire to scientifically validate the medicinal properties of these plants has resulted in the investigation of their various biological activities. There are dearth of information on the antimicrobial potentials of *E. heterophylla* although [12] reported the antibacterial activities of leaves extract against strains of typed culture organisms.

Cassava (*Manihot esculenta*) is an important root crop in the tropics [13]. In West Africa, this crop is usually fermented using various methods before consumption [14]. One of the most

popular foods derived from fermented cassava is cassava flakes popularly known as *garri*, which is consumed by nearly 200 million people in West Africa [15]. Cassava is the staple food of 250 million of Africans [15]. Different kinds of foods result from cassava processing, e.g. “*garri* and *fufu*”, which are fermented cassava derived foods consumed at least once a day by West African people.

Cassava flakes is a dry granular meal made from moist, lactic acid fermented product of cassava roots. Cassava flakes can be processed with carotenoid-rich palm oil (yellow *garri*) or without palm oil (white *garri*). This product is widely acceptable and consumed by both the rich and poor in Nigeria. Many of the fermented products consumed by different ethnic groups have therapeutic values, some of the most widely known are fermented milks (that is, yoghurt, curds) which contain high concentrations of probiotic bacteria that can lower the cholesterol level [16], Improvement of nutrients absorption and digestion, restores the balance of bacteria in the gut to hinder constipation, abdominal cramps, asthma, allergies, lactose and gluten intolerance [17]. The slurries of carbohydrate based fermented Nigerian foods such as *ogi*, *fufu* and *wara* have been known to exhibit health promoting properties such as control of gastroenteritis in animals and human [18,19].

Some microorganisms involved during the fermentation produce antimicrobial products [20] that are beneficial. Previous study on *Euphorbia heterophylla* and folk medicinal believe of the Ife people (Yoruba speaking people of Nigeria) is that when *Euphorbia heterophylla* is mixed with *garri*, it cures typhoid and some are even of the opinion that it is more effective with red *garri*. This research is therefore focused on the *in vivo* effect of cassava flakes mixed with *euphorbia heterophylla* against *Salmonella typhi*.

## 2. MATERIALS AND METHODS

### 2.1 Collection of *Euphorbia heterophylla*

Fresh intact leaves of *Euphorbia heterophylla* were obtained from a local garden in Iyana church area of Ibadan, Oyo State, Nigeria.

### 2.2 Collection of Test Organism

Pure isolate of *Salmonella typhi* was obtained from the Microbiology research laboratory of the University of Technology, Akure, Ondo State, Nigeria.

### 2.3 Antimicrobial sensitivity Test of the *Euphorbia heterophylla* extract

The antimicrobial test was carried out using the agar diffusion method described by [21]. The test organism was inoculated on already prepared Nutrient agar plate and spread uniformly with sterile glass spreader. Cavities of 1 cm diameter were made on the nutrient agar using a sterile cork borer. 0.1 ml of the plant extract was introduced into each of the cavities. Sterile distilled water was introduced into one of the cavities as positive control. The plates were allowed to stand for 1 hour on the bench for diffusion to occur. Plates were thereafter incubated at 37°C for 24 to 48 hours. The diameter of zones of inhibition were then observed and recorded.

### 2.4 Laboratory Experimental Rats

Eight to ten weeks old albino rats of weights ranging from 124 g to 180 g were used for the experiment. These rats were obtained from Animal Production and Health Laboratory, Federal University of Technology Akure, Ondo State, Nigeria. The rats were fed with grower's mash throughout the period of the experiment.

### 2.5 Treatment of infected Animals

Twenty one albino rats of both sexes were classified into three with each group having seven animals each, the animals were allowed free access to water and food pellets. The animals in (a) and (b) were infected with *Salmonella typhi* orogastrically, those in group (a) were treated with *Euphorbia heterophylla* mixed with yellow cassava flakes and those in group (b) were treated with *Euphorbia heterophylla* mixed with white cassava flakes.

The animals in the control group (c) were fed with only the grower's mash throughout the period of the experiment.

### 2.6 Culturing and Harvesting of *Salmonella typhi* Cells

Two loopful of *Salmonella* pure culture was inoculated into 500 ml of sterile nutrient broth and incubated at a temperature of 37°C for 24 hours. After incubation, it was centrifuged for 15 minutes at a speed of 3000 rpm. The pellets were rinsed into a sterile flask. Serial dilution was prepared by aseptically pipetting 1 ml of the *Salmonella* stock culture into 9 ml of distilled water in a test tube and thoroughly mixed to give a dilution of  $10^{-1}$ , 1 ml of  $10^{-1}$  dilution was pipetted into another test tube containing 9 ml of sterile distilled water using a fresh pipette to make a dilution of  $10^{-2}$  and subsequently to dilution  $10^{-7}$ .

### 2.7 Feeding of Albino Rats with *Salmonella typhi*

Two ml of *Salmonella typhi* from the  $10^{-7}$  dilution was orogastrically ingested using the feeding loop. Observations were made hourly to determine if there would be any infection, time of infection and the number of rats infected.

### 2.8 Widal Test Analysis

Widal test on the rats' blood samples was done according to the method of [21]. The whole blood was collected into labelled EDTA bottles and centrifuged at 1500 rpm for 10 minutes to separate the serum from the cells. The serum was carefully withdrawn and titrated against standard antisera following the manufacturer's instructions. The results were then recorded with 1:40 taken as significant titre value.

### 2.9 Preparation of garri Using *Euphorbia heterophylla*

One hundred gram of *Euphorbia heterophylla* was weighed into 1000 ml of boiling water, sieved and used to prepare *Eba* using yellow and white cassava flakes in separate sterile plates.

### 2.10 Histological Studies

Male and female Swiss albino rats (8-10 weeks old) weighing 100-140 g were obtained from the Department of Animal Production and Health, Federal University of Technology, Akure, Nigeria.

The animals were housed in separate cages, kept in a clean environment and fed with food and water *ad libitum* (2 g of the *Euphorbia-gari* mixture for 7 days). The animals were dozed with chloroform and the various organs (heart, kidney, liver) were removed, grossly examined and stained with haematoxylin-eosin before examining under the light microscope if the treatment has any effect on them. The organs were compared with that of the control rats. The histological processing was carried out and interpreted at the Department of Animal Production and Health Laboratory, Federal University of Technology, Akure, Ondo State.

### 2.11 Statistical Analysis

Analysis of variance (ANOVA) and Duncan's multiple comparison tests among data were carried out using SPSS and MS Office Excel software for the significance of the main effects (factors), and treatments along with their interactions.

## 3. RESULTS AND DISCUSSION

The results obtained from the analyses showed that the infectivity dose of the animals vary according to their body weight. However the average infectivity dose of the organisms on the animals was  $2.0 \times 10^2$  cfu/ml. Table 1 showed the result of the antibacterial evaluation of the *Euphorbia heterophylla* extract. Comparatively, the least effective was the aqueous extract of *Euphorbia heterophylla*; while the most effective was *Euphorbia heterophylla* + white cassava flakes. However, ciprotab (a standard commercial antibiotic) was most effective, having the highest diameter of zone of inhibition. The results of the widal test performed on the experimental animals before, during and after infection as well as after treatment for 3 days and 7 days respectively shows that the infection of the animals caused significant increase in the titre values obtained. This is shown in Table 2. For instance, the titre value for *Salmonella typhi* before infection was 1:20, during infection, it rose to 1:160 and treatment began, it dropped gradually to 1:40 and by the 7<sup>th</sup> day of the inception of treatment it was 1:20 again.

The result of the histopathological studies showed that there were mild to severe

pathological changes majorly varying from widespread vascular damage, haemorrhage, vasculitis, cellular degeneration and necrosis. The kidneys of the rats infected with *Salmonella* and treated with both the mixture of *Euphorbia heterophylla* and white or yellow *garri* respectively showed mild interstitial mononuclear cell infiltrations with slight tubular necrosis that resulted in glomerular shrinkage of the Bowman's capsule. The control had normal nephrotic cells without any degeneration. This is shown in plates 1a, b and c respectively. The histopathology of the liver presented showed varying degrees of vacuolar degeneration which appears slightly swollen for the group fed with *Euphorbia heterophylla* mixed with red cassava flakes. Mild microsclerosis and fatty degeneration of hepatic cells leading to necrosis of the hepatocytes, Haemorrhage and widening of blood sinusoids were also observed for the rats fed with *Euphorbia heterophylla* mixed with white cassava flakes. The control group showed mild microsclerosis and fatty degeneration of hepatic cells. This is shown in plates 2a, b and c respectively.

**Table 1. Antimicrobial evaluation of the *Euphorbia heterophylla* extract**

Extract	<i>Salmonella typhi</i>
Aqueous Extract of <i>Euphorbia heterophylla</i>	12±2.0
<i>Euphorbia heterophylla</i> + Yellow cassava flakes	14±1.0
<i>Euphorbia heterophylla</i> + White cassava flakes	18±0.21
Ciprotab	23±1.4

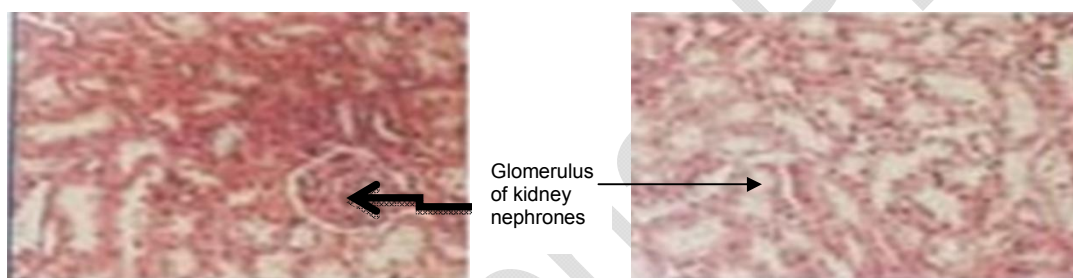Values are mean ± SD of three replicates.

The heart of the rat fed with the red /white cassava flakes mixed with *Euphorbia heterophylla* is shown in plates 3a, b and c. Histopathological examination reveals myocardites with fragmentation of myofibrils in the group fed with the mixture of *Euphorbia heterophylla* and red cassava flakes, while the group fed with the mixture of *Euphorbia heterophylla* and white cassava flakes showed vascular degeneration of mononuclear cell infiltration, thrombosis and vasculitis of the cardiac muscles. The control showed normal cardiac muscles with slight cell infiltrations of the striata.

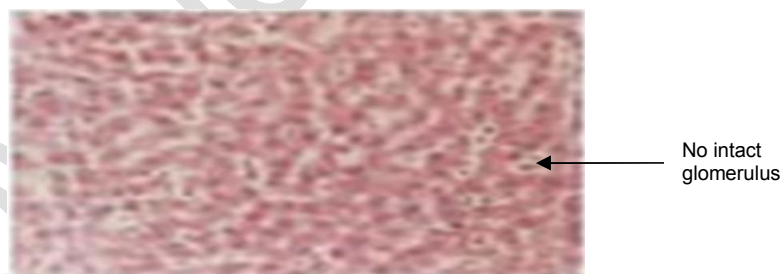**Table 2. Titre values of widal test results obtained from experimental albino rats before, during and after infection**

Samples	<i>Salmonella typhi</i>	<i>Salmonella paratyphi A</i>	<i>Salmonella paratyphi B</i>	<i>Salmonella paratyphi C</i>
A1	1:20	1:40	1:20	1:40
A2	1:20	1:20	1:40	1:20
A3	1:20	1:40	1:40	1:40
B1	1:80	1:80	1:40	1:80
B2	1:160	1:160	1:80	1:80
B3	1:80	1:80	1:80	1:160
C1	1:40	1:40	1:80	1:40
C2	1:40	1:20	1:40	1:20
C3	1:40	1:20	1:40	1:20
D1	1:20	1:20	1:40	1:20
D2	1:20	1:20	1:40	1:20
D3	1:20	1:20	1:20	1:20

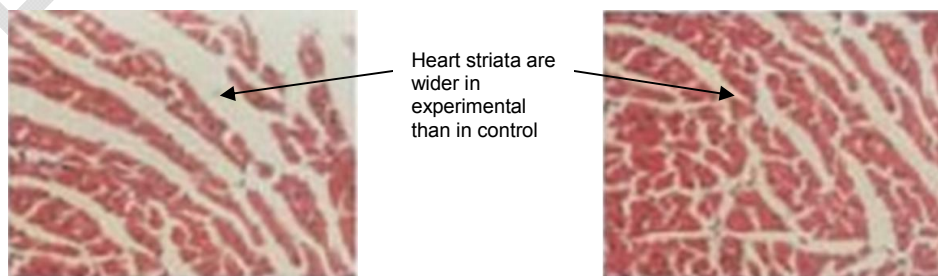
A: Before infection; B: After infection; C: 3 days after treatment administration; D: 7 days after treatment administration



**Plate 1a. Kidney of infected rat and treated with white garri; Plate 1b. kidney of the control**

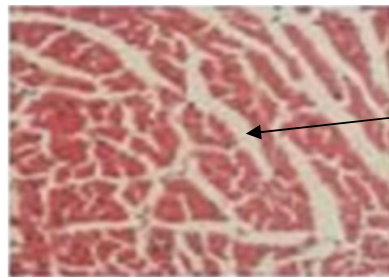


**Plate 1c. Kidney of infected rat and treated with yellow garri**



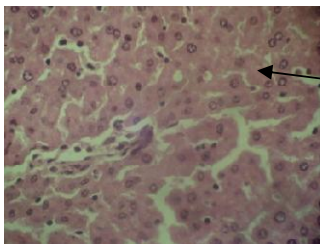
**Plate 2a. Heart of infected rat and treated with white garri**

**Plate 2b. Control**

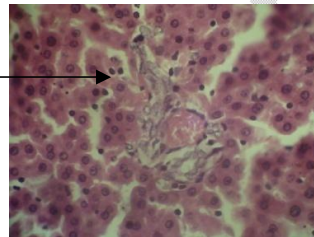

Normal heart striata as in control

**Plate 2c. Heart of infected and treated with yellow garri**

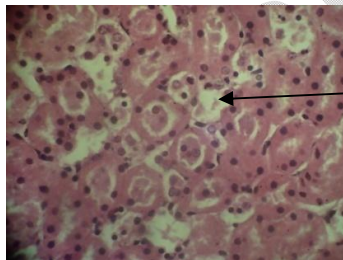


Liver hepatocytes have intact sinusoids without drainage



**Plate 3a. Liver of infected rat and treated with white garri**

**Plate 3b. Control**



Intact liver hepatocytes with prominent cells

**Plate 3c. Liver of infected rat and treated with red garri**

#### 4. DISCUSSION

From the result obtained in the antibacterial evaluation of the *Euphorbia heterophylla* extract (Table 1) showed that the plant has antibacterial property against *S. typhi*. According to [22], any substance that is able to exert a zone of inhibition of 6 mm and above has antibacterial activity against such bacteria. The titre values obtained (Table 2) for the WIDAL test carried out on the animals before, during and after infecting as well as after treatment also confirmed that the animals were infected and that the organism caused the infection. Equally, the end result of the titre value of the WIDAL test confirmed the therapeutic efficacy of the *Euphorbia heterophylla* mixture. The histopathological analyses of the organs showed that the treatments caused visible pathological changes of the organs. The kidneys showed mild changes such as wide spread vascular damage,

haemorrhage, vasculitis and mild interstitial mononuclear cell infiltration and tubular degeneration. These are probably the damages caused by the organisms according to [23], these signs indicates the infection of *Salmonella typhi*. However, the fact that they are mild indicates the effectiveness of the therapeutic agent being used for treating the infection. The liver sinusoids were found in place and the liver hepatocytes were not spacious as the therapeutic agent contained no detoxicant for the liver to detoxify which means that it is a good therapeutic agent. The heart muscle striata were unaffected and no cardiac puncture as well as heart muscle necrosis. According to [24] any substance introduced into the digestive system or circulatory system that do not exert these effects have therapeutic efficacy. The therapeutic agents therefore contained no deleterious substances that could cause these damages in the organs of the animals. It is conceivable from the results obtained that

*Euphorbia heterophylla* mixed with yellow and white *gari* can be used in the control of *Salmonella typhi* infections, especially the problems caused in the liver and kidney by the organism. It can be used to treat disruptions in the kidney and liver. The gross result showed that the therapeutic efficacy of these mixtures are outstanding and therefore holds high hope that if adequate purification measures are used and proper harnessing of the therapeutic ingredients are done, it can help in the development of novel antibacterial agents and equally help to combat resistant *Salmonella typhi*.

## 5. CONCLUSION

The results obtained in this work showed that *Euphorbia heterophylla* mixed with cassava flakes is an effective therapeutic agent for Salmonellosis and that the *Euphorbia heterophylla* with white cassava flakes mixture is more effective in the treatment of salmonellosis.

## CONSENT

It is not applicable.

## ETHICAL APPROVAL

“All authors hereby declare that all experiments have been examined and approved by the appropriate ethics committee and have therefore been performed in accordance with the ethical standards laid down in the 1964 Declaration of Helsinki.”

## ACKNOWLEDGEMENTS

The authors wish to acknowledge the staff of post graduate Microbiology laboratory, Department of Animal Production and Health Laboratory and Chemistry laboratory of The Federal University of Technology, Akure, Ondo State, Nigeria for their assistance.

## COMPETING INTERESTS

Authors have declared that no competing interests exist.

## REFERENCES

1. Wray C, Davies RH. *Enterobacteriaceae*. In Poultry Diseases. 5<sup>th</sup> edition. EDs F; 2002.
2. Wales J. A personal appeal from wikipedia foundation, Inc. U.S. 2008;2-7.
3. World Health Organization (WHO). Salmonellosis Control: The Role of Animal and Product Hygiene, Technical Report Series, 774, WHO, Geneva; 1998.
4. Egharevba RKA, Ikhatua MI. Ethnomedicinal uses of plants in the treatment of various skin diseases in Ovia North East, Edo State, Nigeria. Nigerian Tribune. 2008;1-4.
5. Jones WP, Waston RP, Wallis ST. Salmonellosis. Bovine Medicine: Diseases and Husbandry of Cattle. 2<sup>nd</sup> ed. UK: Blackwell Science. 2004;215-230.
6. Hohmann EL. Non-typhoidal salmonellosis. Clinical Infectious Diseases. 2001;32:253-269.
7. Wrebid T, Jordan, Pattison M, Alexander D, Faragherw T, Sanders B. General animal pathology. Living Stone Publisher. 2010;96-109.
8. Bentancur-Galvis LA, Morales GE, Forero JR. Cytotoxic and antiviral activities of Columbian Medicinal plant extracts of the *Euphorbia* genus. Mem Inst. Oswaldo Cruz, Riode Janeiro. 2002;97(4):541-546.
9. Clarke ML, Harvey DG, Humphrey DJ. Veterinary toxicology. 2<sup>nd</sup> edition. Bailliere Tindall, London. 1991;219.
10. Burkegharevba R. K. ill, H. M. The useful plants of west tropical Africa. Roy. Bot. gard. Ken. 1994;(2):12-15
11. Akobundu I, Okezie A, Agyakwa CW. A handbook of West African Weeds. Second Edition. African Book Builders Ltd. 2 Awosika Avenue, Bodija U.I. P.O. Box 20222 Ibadan. 1998;260-261
12. Brock TD, Madigan TM. Biology of Microorganisms. Fifth edition. Prentice International, Inc. 1988;541-544.
13. Prescott LM, Harley JP, Klein DA. Microbiology. Fifth edition McGraw Hill Publishers, USA. 2002;926-933.
14. Radostits OM, Gay CC, Hinchcliff KW, Vonstable PO. Veterinary medicine, a text book of the disease of cattle, horses, sheep, pigs and goats. 10<sup>th</sup> ed. London: Saunders Elsevier. 2007;896-921.
15. Al-Burtamani SKS, Fatope MO, Marwah RG, Onifade AK, Al-Said AS. Chemical composition, antibacterial and antifungal activities of the essential oils of tubercalution from Oman. J. Ethnopharm. 96: 107-112 Acute toxicity of *Euphorbia heliscopia* in Rats. Pak. J. Nutri. 2005;5(2):135-140.
16. Adedapo AA, Abatan MO, Olorunsogo. Toxic effects of some plant in the genus

- Euphorbia* on haematological and biochemical parameters of rats. Vdet. Arhic. 2004;74:53-64.
17. Salmonellosis. Topic overview on Salmonellosis; 2012. Available:[www.webmd.com/food-recipes/food-poisoning/tc/salmonellosis-topic-overview](http://www.webmd.com/food-recipes/food-poisoning/tc/salmonellosis-topic-overview)
  18. Upadhyal RR, Zarintan MH, Ansarin M. Isolation of Ingenol from the irritant and cocarcinogenic latex of *Euphorbia seguieriana*. Pl. Med. 1980;30:32-34
  19. Morgan HR. Typhoid fever, Microsoft. Student 2007 (DVD) Redmond, W.A. Microsoft Corporation; 2007.
  20. Available:<http://en.wikipedia.org/wiki/salmonella>
  21. Walderhand M. Food borne pathogenic microorganisms and natural toxins, handbook U.S. food and drug administration. Centre for Food Safety and Applied Nutrition. 2007;3-5.
  22. Trongtokit Y, Rongsriyam Y, Komalamisra N, Apiwathnasorn C. Comparative Repellants of 38 essential oils against mosquito bites. Phytotherapy Research. 2005;19(4):303-9.
  23. White DG, Zhao S, Sudler R, Ayers S, Friedman S, Chen S, Mcdermott S, Waner DD, Meng J. The isolation of antibiotic-resistant *Salmonella* from retail ground meats. New Engl. J. Med. 2001;345(16):1147-1154.
  24. Clark MA, Barret EL. The p<sub>h</sub>s gene and hydrogen sulphide production By *Salmonella typhimurium*. J Bacteriology. 1987;169(6):2391-2397.

© 2015 Omoya et al.; This is an Open Access article distributed under the terms of the Creative Commons Attribution License (<http://creativecommons.org/licenses/by/4.0>), which permits unrestricted use, distribution, and reproduction in any medium, provided the original work is properly cited.

Peer-review history:

The peer review history for this paper can be accessed here:  
<http://www.sciencedomain.org/review-history.php?iid=1017&id=13&aid=8147>