

See discussions, stats, and author profiles for this publication at: <https://www.researchgate.net/publication/348436055>

# The Evaluation of the Effects of Orange Juice on the Microflora, Haematology and Selected Organs of Albino Rats

Article in *Journal of Probiotics & Health* · January 2021

CITATIONS

0

READS

13

1 author:



**Abdul Onoruoiza Momoh**  
Elizade University

26 PUBLICATIONS 36 CITATIONS

SEE PROFILE

Some of the authors of this publication are also working on these related projects:



Comparative studies [View project](#)



Nutraceutical and gastrointestinal microbiology [View project](#)

# The Evaluation of the Effects of Orange Juice on the Microflora, Haematology and Selected Organs of Albino Rats

Momoh AO\* and Loyibo E

Department of Biological Sciences, Elizade University, Ilara-Mokin, Ondo State, Nigeria

## ABSTRACT

Fresh oranges juice is an excellent source of vitamin C and contains powerful natural antioxidant, folate, dietary fibre and other bioactive components. The effects of fresh orange juice on the microflora, haematology and histopathology of selected organs of albino rats was evaluated using standard methods. Different volumes of the juice were fed to the rats daily for 8 weeks. Their weight was taken every other day and a comprehensive assessment of their hematology, gastrointestinal flora and histopathology of selected organs done. The juice did not cause any pathological degeneration of the tissue or organs assessed. It caused increased in Packed Cell Volume (PCV) of the rats with the highest increase observed in the rats given 1.0 ml of the juice daily. The PCV was  $51.22 \pm 1.24\%$  for the group given 1.0 ml daily while the control group was  $41.33 \pm 0.67\%$ . All the results for the PCV were significantly different at  $P \leq 0.05$ . None of the rats gut was sterile with 7 bacteria identified. The bacteria load ranges from  $1.3 \times 10^2$  cfu/ml to  $1.9 \times 10^4$  cfu/ml. The group fed with 0.5 ml of the juice had the highest weight gain. The results obtained has proof the effect of fresh orange juice as a source of vitamin. The histopathological results of the selected organs showed that they are pathologically fine without any degeneration of tissues thereby providing evidence that fresh orange juice has prophylactic and therapeutic values. Conclusively, fresh orange juice has medicinal values, boost immunity, increase blood volume, and restore normal gastrointestinal microflora.

**Keywords:** Fresh orange juice; Effects; Gut microflora; Histopathology; Weight; Haematology

## INTRODUCTION

Plants have anchored to the earth long before man began to multiply on it. These plants as well as other materials were present for the survival of man before his arrival on earth. The World Health Organization (WHO) estimates that about 80% of the world's population still depends upon herbal medicines for the treatment of various diseases due to easy availability, economic reasons and lesser side effects than drugs [1]. Citrus is widely grown in Nigeria and many other tropical and subtropical regions [2]. In terms of volume in production, and with over 108 million tons, citrus is the world second fruit crop after banana.

Sweet orange (*Citrus sinensis* L. Osbeck) commonly called orange is a member of this family and a major source of vitamins (especially vitamin C), sufficient amount of folacin, calcium, potassium, thiamine, niacin and magnesium [3]. Economically, oranges are important fruit crops, with an estimated 60 million

metric tonnes produced worldwide as at 2005 for a total value of 9 billion dollars. Of this total, half came from Brazil and the United States of America as reported by [4]. The global citrus acreage according to FAO statistics in 2009 was nine million hectares with production put at 122.3 million tons, putting sweet oranges above all the fruit crops [5].

The human Gastrointestinal Tract (GIT) is colonized within the first days of life by microbes that contribute the digestion and immune system among others [6]. It is one of the most complex ecosystems on earth and contains members of all tree domains: Archaea, Eukarya and Bacteria, which predominate in this environment. The vast arrays of bacterial cells in the human GIT are ten times more numerous than number of the body cells in total [7]. Intestinal microbiota includes microorganisms colonizing such parts of gastrointestinal tract as the small intestine (jejunum and ileum), colon and rectum. Microbiota of

\*Corresponding author: Momoh AO, Department of Biological Sciences, Elizade University, Ilara-Mokin, Ondo State, Nigeria, Tel: +2348036530924; E-mail: [abdul.momoh@elizadeuniversity.edu.ng](mailto:abdul.momoh@elizadeuniversity.edu.ng)

Received date: December 17, 2020; Accepted date: December 31, 2020; Published date: January 07, 2021

Citation: Momoh AO, Loyibo E (2021) The Evaluation of the Effects of Orange Juice on the Microflora, Haematology and Selected Organs of Albino Rats. J Prob Health. 9:230.

Copyright: © 2021 Momoh AO. This is an open-access article distributed under the terms of the Creative Commons Attribution License, which permits unrestricted use, distribution, and reproduction in any medium, provided the original author and source are credited.

these parts of the digestive system is much more diverse and larger than the population of upper parts of GIT. Guarner et al. reported that the GIT ecosystem consists of 17 families, 45 genera and over 1,000 species of microorganisms but the development of diverse biocenosis can be positively affected by slower movement of gastric contents and increase in pH by a significant amount (gastric pH is 1.0-2.0 unit while in the mucosa of the small intestine may be even 8.0) [6,8].

Majority of gut bacteria is anaerobic (facultative or obligate), however the intestinal mucus is a favorable environment for the growth and existence of microaerophiles [9]. In the adult human gut microbiota *Bifidobacterium*, *Bacteroides*, *Clostridium* and *Eubacterium* dominate, less from the genus *Lactobacillus*, *Escherichia*, *Enterobacter*, *Streptococcus* or *Klebsiella*. In the case of breast-fed infants 60-90% of the bacteria belong to genus *Bifidobacterium*, less to *Bacteroides* and *Lactobacillus* (below 1%). Predominant bacterial species are only 30% of microorganisms present in the gut of every human being; the remaining 70% are unique micro-organisms [9].

The human diet contains vitamins C and E, carotenoids and flavonoids which are important micronutrients that are essential for maintenance of human health. These dietary sources and many more of these compounds are present in all plant material. The nutritional importance of foods is due to the presence of these functional food ingredients and antioxidant nutraceuticals or phytochemicals. Phytochemicals are present in edible fruits and vegetables and when eaten potentially modulate human metabolism in a favourable manner, thereby prevent chronic and degenerative diseases [10]. Citrus fruits are the main source of important phytochemical nutrients and for long have been valued for their wholesome nutritious and antioxidant properties. It is scientifically proven that oranges being rich in vitamins and minerals have many health benefits. Moreover, it is now appreciated that other biologically active, non-nutrient compounds found in citrus fruits such as phytochemical antioxidants, soluble and insoluble dietary fibres are known to be helpful in reducing the risk for cancers, many chronic diseases like arthritis, obesity and coronary heart diseases [11].

The human diet contains important micronutrients namely vitamins C and E, carotenoids and flavonoids, essential for maintenance of human health and there are many dietary sources of these compounds which are present virtually in all plant material [12]. These functional food ingredients and antioxidant nutraceuticals or phytochemicals account for the nutritional importance of food. Tripoli et al. stated that phytochemicals are present in edible fruits and vegetables and when eaten potentially modulate human metabolism in a favorable manner, thereby prevent chronic and degenerative diseases [10]. Thus, citrus fruits are the main source of important phytochemical nutrients and for long have been valued for their nutritious and antioxidant properties. It is scientifically proven that oranges are being rich in vitamins and minerals have many health benefits. Moreover, it is now an appreciable fact to science and the world at large that other, non-nutrient compounds (however still active), are found in citrus fruits. Examples are phytochemicals antioxidants, soluble and insoluble dietary fibers. These are known to be helpful in

reducing the risk of cancers, many chronic diseases like arthritis, obesity and coronary heart disease.

Oranges as excellent source of vitamin C, contain powerful natural antioxidant, folate, dietary fibre and other bioactive components, like carotenoids and flavonoids that prevent cancer and degenerative diseases. Consumption of foods rich in vitamin C improves body immunity against infectious agents and scavenging harmful, pro-inflammatory free radicals from the blood. Sweet orange contains a variety of phytochemicals like hesperetin and naringenin. Naringenin has a bioactive effect on human health as antioxidant, free radical scavenger, anti-inflammatory, and immune system modulator [13].

Oranges are popular due to their natural sweetness, the many different types available, and the diversity of uses. The reality of the situation is that yes, a glass of orange juice does indeed contain vitamin C which generally improve the immune system, but that fact hardly outweighs the fact that Orange juice is high in sugar and calories, which may contribute to weight gain and high blood sugar. Despite its high sugar content, it is preferable to take orange juice than soft drinks because of its high nutrient content. Unlike fruit juices, soda contains nothing but empty calories. Fruit juices, on the contrary, are loaded with antioxidants and micronutrients. The key is to enjoy them in moderation. The need to evaluate the effect on animals cannot be over emphasized. This prompted the need to evaluate the effect of orange juice microbiologically as it affects the gastrointestinal tract flora and also organs specifically the liver and kidney.

## MATERIALS AND METHODS

### Collection of experimental rats

The experimental albino rats used for this research were young adults Whister albino rats of six (6) weeks old. They were obtained from the animal house of the Obafemi Awolowo University (OAU) research farm. They were confirmed to be apparently healthy by the veterinary doctors of the research farm before they were purchased.

### Sources of orange juice

Fresh orange juice was obtained by purchasing fresh oranges from Ilara-Mokin central market and squeezing the juice out into a clean container every other day. It is from this container that the juice was then dished out for the animals.

### Experimental design

The experimental design was done by grouping the rats into four groups (A, B, C and D). Each group consists of three (3) rats that were fed with the same volume of orange juice daily. They were fed for eight (8) weeks before terminating the experiment. The layout of the experiment was done according to the method of Omoya and Momoh [14].

## Feeding of experimental rats

The experimental rats were allowed to acclimatize for a period of two weeks (14 days) before dividing them into their various groups. Group A was given 0.25 ml daily, Group B was given 0.50 ml daily, Group C was given 1.00 ml daily and group D served as the control.

## Blood collection

Anaesthetization method as described by Adebolu et al. was used for the collection of blood from the rats used in this experiment [15]. The blood collected was carefully transferred into EDTA bottles for haematological assays and liver functioning tests respectively. Cardiovascular puncture was used to withdraw blood from rats whose organs were not needed for histopathology analysis.

## Organ collection

For histopathological assays, organs such as the liver and kidneys were dissected out using a clean set of dissecting tools from apparently healthy albino rats. These organs were collected into specimen bottles containing 10% formalin according to standard method by Baker et al. [16].

## Haematological tests

Haematological tests such as Packed Cell Volume (PCV), Hemoglobin Concentration (HB), Red Blood Cell Count (RBC), Erythrocyte Sedimentation Rate (ESR), White Blood Cell Count (WBC) and White Blood Cell differential count were done according to Cheesbrough using the following materials: Blood samples [17]. Microscope, slides, Giesma stain, capillary tube, spectrophotometer, Leishman stain, EDTA bottles, haematocrit centrifuge were used for this assay as follows:

**Erythrocyte Sedimentation Rate (ESR):** A wintrobe tube was filled to the top 0 mark and one end of it blocked with plastacine. It was stand in an upright position undisturbed for 1 hr. The distance of the fall of red cells in it was read and expressed as the mm fall per hour as the ESR.

**Packed Cell volume (PCV):** Blood collected into an anticoagulant bottle was mixed and a capillary tube was filled up to 75% (3/4) of its length and placed in the micro-haematocrit centrifuge with the sealant at the outer end and centrifuged at 12,000 rpm for 5 minutes. The result was read as a percentage of packed red cells to total volume of whole blood using a haematocrit reader.

**Red Blood cell count (RBC):** The blood sample was diluted 1:200 and mixed properly. A portion (0.02 ml) of the blood was pipetted into 4 ml of diluting fluid in a bijou bottle and washed thoroughly by alternately drawing up and expelling the diluting fluid. A fine Pasteur pipette was used to fill the counting chamber and the RBC counted using a counter under  $\times 40$  objectives.

**White Blood Cell count (WBC):** The blood was first diluted in ratio 1:20 and 0.05 ml of the blood was pipetted into 0.95 ml of

diluting fluid. A little portion (0.2 ml) was introduced into the counting chamber and observed using  $\times 10$  objective to count the white cells/cubic mm.

**Haemoglobin (Hb):** Using mouthpiece sucker and a 0.02 ml pipette, blood was withdrawn and introduced into 4 ml Drabkin's solution in a tube. The tube was stoppered, mixed and allowed to stand for 5 minutes for full colour development. A standard blood sample of known haemoglobin concentration was prepared. Using a green (624) filter, the colorimeter was set to zero using plain Drabkin's solution as a blank. The readings of the sample and the standard were taken and the result calculated as follows:

Sample haemoglobin concentration = Reading of test  $\times$  standard haemoglobin concentration / Reading of standard

**White Blood Cell Differential (WBC Differential) count:** Twenty microlitre (0.20 ml) of whole blood was placed on clean grease-free slide and made into a thin film using a glass rod. The film was allowed to air dry before staining with Giesma stain. The stained slides were air dried and observed under immersion using  $\times 100$  objective under the microscope. The cells were counted and their numbers recorded individually in terms of neutrophils, eosinophils, basophils, lymphocytes and monocytes based on their shapes as documented by Yamada [18].

## Histopathological tests

Histopathological test on the pancreas was performed according to the methods of Baker et al. and Cheesbrough in the following process:

**Fixation:** Fixation of the tissue was done to prevent further enzymatic activity that usually leads to post-mortem autolysis. It also hardens tissue as well as kills microbes and keeps the tissue in its original form. The organs of the animals were collected and fixed in 10% buffered formalin.

**Trimming:** After fixation, the organs were trimmed to about 1-2 cm before dehydration.

**Dehydration:** Dehydration was done by passing the tissue through different concentrations of ethanol. It was done by the use of automatic tissue processor. They were dehydrated in graded percentages (50%, 70%, 80% and 100%) of ethanol for 1 ½ hours each at  $30 \pm 2^\circ\text{C}$ .

**Clearing:** Clearing of dehydrated tissue was done using 100% xylene. The tissues were left for 2 hours to remove any remnant alcohol completely.

**Embedding:** This was the placing of the cleared tissue in melted paraffin and allowed to harden. The tissues were left in the molten paraffin wax for 2 hours to embed properly.

**Sectioning:** This was done using a microtome. The tissues were sectioned to about 3-10  $\mu$  and floated in water bath at  $37^\circ\text{C}$ .

**Hydration:** This is the process of passing the tissue through water by passing it through different concentrations of alcohol. It was passed through xylene, 100%, 90%, 80%, 70% and 50% of ethanol for 1 1/2 hours at each concentration.



**Staining:** This was done using Haematoxylin and Eosin (H and E) stains. Haematoxylin stains the nucleus blue while eosin stains the cytoplasm acidophilic.

Dehydration, fixing and microscopy of stained slides:

Dehydration was done again by passing the tissue through different concentrations of ethanol. It was done by the use of automatic tissue processor. The tissues were dehydrated in different percentage (50%, 70%, 80% and 100%) of ethanol for 1 ½ hours each and cleared with xylene. The method of Cheesbrough was used to remove excess stain under tap water [17]. After clearing in xylene, the fixed tissue on a glass slide was fixed with canada balsam and covered with cover slips. The preparations were left in the oven at 40°C and then placed under the photo-microscope for examination [19].

**Bacterial isolation**

The small intestine of the albino rats was aseptically dissected out into a sterile specimen bottle containing 9 ml sterile distilled water. It was vigorously shaken and one ml of it taken for microbial load analysis and microbial type evaluation respectively using the method of Omoya and Momoh [14]. Each analysis was done in triplicates. The stepwise isolation of the microflora from the intestine of the experimental rats was done using prepared differential and enrichment media as described by Cheesbrough [17].

**Statistical analysis**

Data obtained were subjected to descriptive one way analyses of variance using SPSS version 22 and Duncan New multiple range tests was used as follow up test.

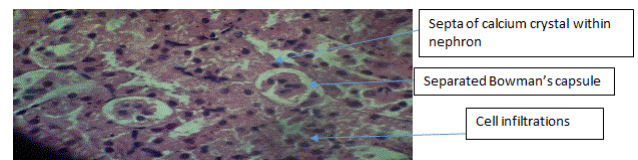
**RESULTS**

The histopathological analysis of the kidney of the experimental rats showed features that are pathologically fine without any degeneration of tissues. These include features such as mild interstitial mononuclear cell infiltrations, complete tubular generation of Bowman’s capsules, absence of necrosis and glomerular shrinkage. There is no form of glomerular basement collapse neither is there any form of glomerular shrinkage. No haemorrhage seen and no collapse of any of the nephrotic vein or renal arteries. There are some with the presence of increased hyaline casts with cell infiltrations. Few inflammatory cell infiltrations are common in mature nephrotic areas.

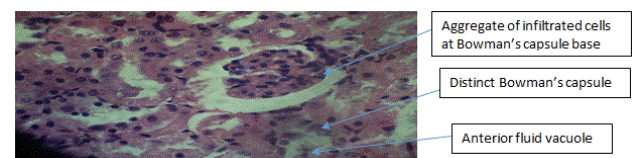
Therefore, throughout the histopathology of the kidneys of the rats, there was no negative pathology sighted both in the control and in the experimental groups. However, the group fed with 0.5 ml of the orange juice daily had the best kidney nephron architectural formation as seen in plates 1-12.

The results of the histopathology of the liver of the albino rats showed no pathologically deformed features that could be of health concern but distinct well-formed hepatocytes. There was no hepatocellular drainage or carbuncle, no wide spread vascular damage of hepatocytes or blood arteries and veins seen, aggregation of lymphatic cells was adequately closed and separation of sinusoids was not noticed. Equally, no necrosis or

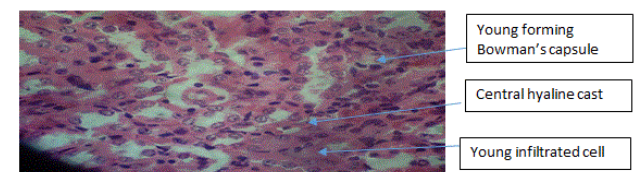
necrotic apoptosis was seen and hemorrhage was not traced along any of the blood vessels. No cellular degeneration of hepatocytes and micro-vesicular fatty infiltrations. The fatty cyst formation of the hepatocytes are adequate with the portal and central venous not congested. In all the liver hepatocytes analyzed, no inflammatory cell infiltrations and no disappearing sinusoids due to karyolysis of any form. The hepatocytes of the control groups tend to be more rigid with distinct formation, an indication of lack of some essential vitamins. These results are shown in plates 1-24.



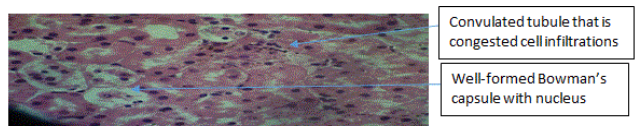
**Plate 1:** Kidney nephrone of rat fed with 0.25 ml of orange juice.




**Plate 2:** Kidney nephrone of rat fed with 0.25 ml of orange juice.



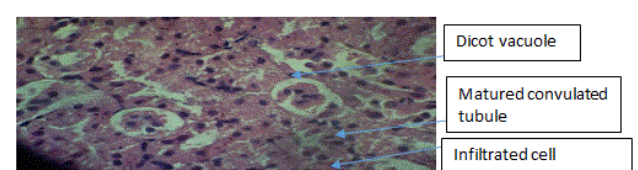
**Plate 3:** Kidney nephrone of rat fed with 0.25 ml of orange juice.




**Plate 4:** Kidney nephrone of rat fed with 0.50 ml of orange juice.



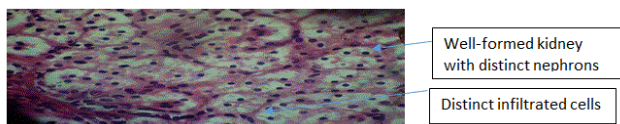
**Plate 5:** Kidney nephrone of rat fed with 0.50 ml of orange juice.



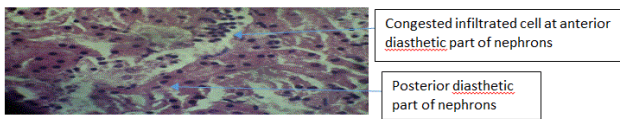
**Plate 6:** Kidney nephrone of rat fed with 0.50 ml of orange juice.




**Plate 7:** Kidney nephrone of rat fed with 1.00 ml of orange juice.



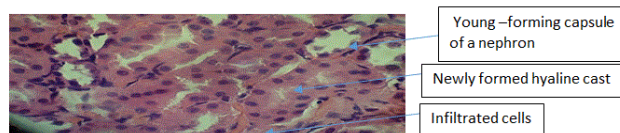
**Plate 8:** Kidney nephrone of rat fed with 1.00 ml of orange juice.



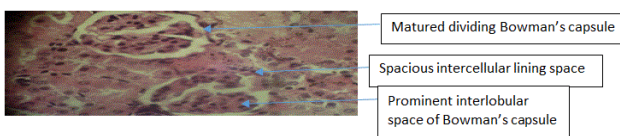
**Plate 9:** Kidney nephrone of rat fed with 1.00 ml of orange juice.



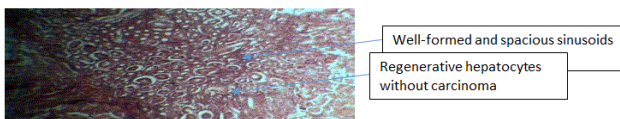
**Plate 10:** Kidney nephrone of rat fed with normal feed (control).



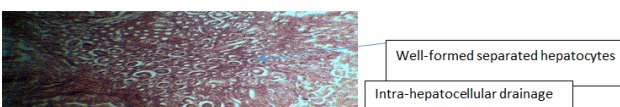
**Plate 11:** Kidney nephrone of rat fed with normal feed (control).



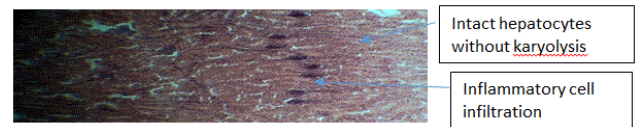
**Plate 12:** Kidney nephrone of rat fed with normal feed (control).




**Plate 13:** Liver hepatocytes of rat fed with 0.25 ml of orange juice.



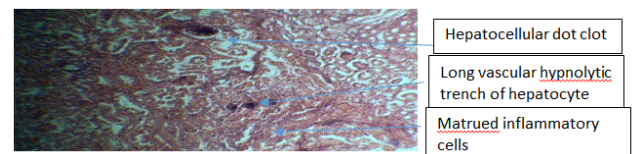
**Plate 14:** Liver hepatocytes of rat fed with 0.25 ml of orange juice.



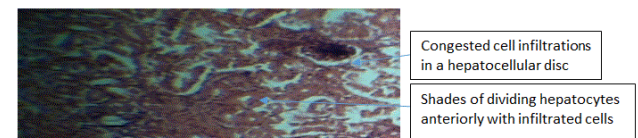
**Plate 15:** Liver hepatocytes of rat fed with 0.25 ml of orange juice.



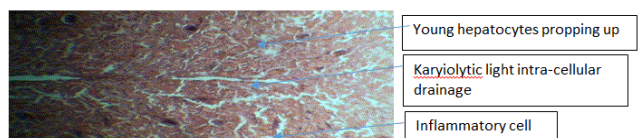
**Plate 16:** Liver hepatocytes of rat fed with 0.50 ml of orange juice.



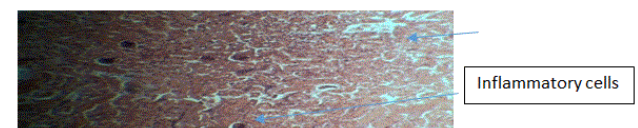
**Plate 17:** Liver hepatocytes of rat fed with 0.50 ml of orange juice.



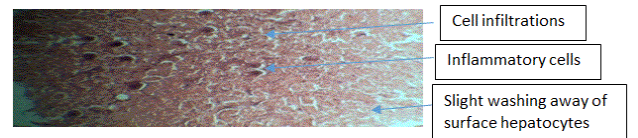
**Plate 18:** Liver hepatocytes of rat fed with 0.50 ml of orange juice.



**Plate 19:** Liver hepatocytes of rat fed with 1.00 ml of orange juice.



**Plate 20:** Liver hepatocytes of rat fed with 1.00 ml of orange juice.



**Plate 21:** Liver hepatocytes of rat fed with 1.00 ml of orange juice.

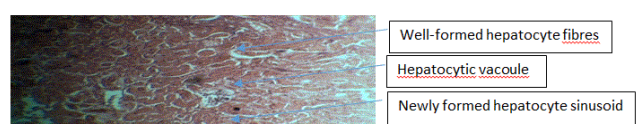




Plate 22: Liver hepatocytes of rat fed with normal feed (control).

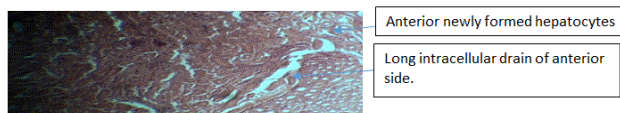


Plate 23: Liver hepatocytes of rat fed with normal feed (control).

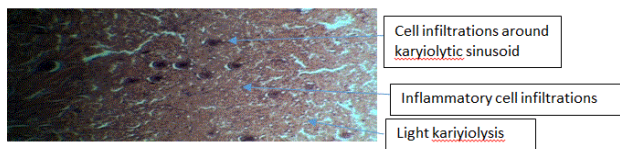


Plate 24: Liver hepatocytes of rat fed with normal feed (control).

The effect of the treatments on the haematological parameters of the rats showed that constant intake of orange juice actually caused increased in the Packed Cell Volume (PCV) of the rats with the highest increase observed in the rats given 1.0 ml of the juice daily. The PCV was  $51.22 \pm 1.24\%$  for the group given 1.0 ml daily while the control group was  $41.33 \pm 0.67\%$ . All the results for the PCV were significantly different at  $P \leq 0.05$ . This pattern was observed for the other parameters except for Erythrocyte Sedimentation Rate (ESR) in which the control group had the highest value of 4.00 mm/hr while the experimental ranges from 1.00-3.00 mm/hr. This result is presented in Figure 1.

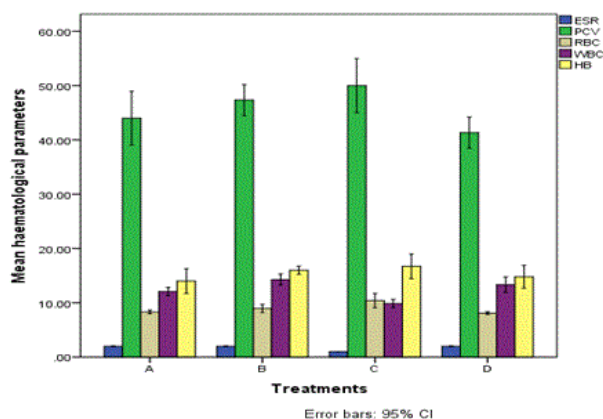


Figure 1: Haematological parameters of albino rats fed with orange juice.

The WBC differential count result showed significant differences in the values obtained for neutrophils, lymphocytes and monocytes respectively. There were no significant differences in value obtained for the neutrophils in the group given 0.25 ml and the control at  $P \leq 0.05$ . There is however significant differences in the group given 0.5 ml and 1.00 ml of orange juice and the control group at  $P \leq 0.05$ . There was also no significant differences at  $P \leq 0.05$  in the values obtained for the all the groups for eosinophils and basophils respectively. The result of the WBC differential count is presented in Figure 2.

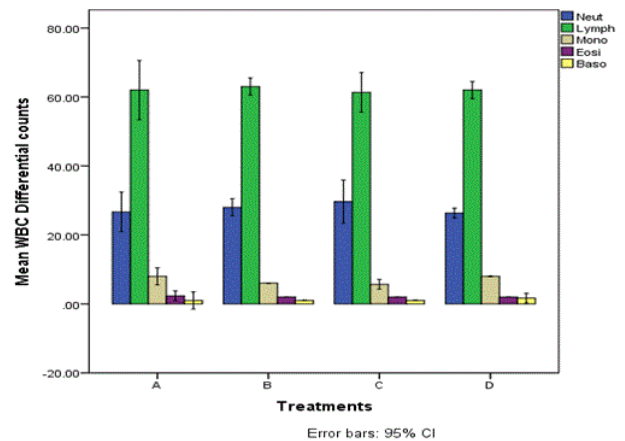


Figure 2: WBC differential parameters of albino rats fed with orange juice.

The results of the microbial analysis of the gut of the experimental rats revealed that none of the rats gut was sterile. The bacteria load ranges from  $1.3 \times 10^2$  cfu/ml to  $1.9 \times 10^4$  cfu/ml. The microbiological analysis of twelve samples of gut specimen showed that seven (7) bacteria were isolated and identified using standard microbiological procedures. These bacteria are *Enterobacter aerogenes*, *Escherichia coli*, *Bacillus cereus*, *Klebsiella pneumonia*, *Citrobacter freundii*, *Lactobacillus* spp and *Pseudomonas aeruginosa*. The results of the bacteria load and identification of types of the bacteria isolated is presented in Tables 1-3 respectively.

Table 1: Bacteria load and types isolated from samples.

Sample no	Sample identity	Bacterial load (cfu/ml)	Bacterial type
1	A1	$1.5 \times 10^3$	<i>Enterobacter aerogenes</i> , <i>Lactobacillus</i> sp, <i>Citrobacter freundii</i> and <i>Pseudomonas aeruginosa</i>
2	A2	$1.3 \times 10^3$	<i>Escherichia coli</i> , <i>Pseudomonas aeruginosa</i> , <i>Enterobacter aerogenes</i> , <i>Lactobacillus</i> sp, <i>Bacillus subtilis</i> and <i>Citrobacter freundii</i>
3	A3	$2.5 \times 10^3$	<i>Enterobacter aerogenes</i> , <i>Lactobacillus</i> sp and <i>Pseudomonas aeruginosa</i>
4	B1	$3.0 \times 10^2$	<i>Enterobacter aerogenes</i> , <i>Lactobacillus</i> sp

									and <i>Citrobacter freundii</i>
5	B2		$2.3 \times 10^2$						<i>Enterobacter aerogenes</i> , <i>Lactobacillus</i> sp, <i>Klebsiella pneumoniae</i> and <i>Bacillus subtilis</i>
6	B3		$3.0 \times 10^2$						<i>Enterobacter aerogenes</i>
7	C1		$1.6 \times 10^2$						<i>Enterobacter aerogenes</i> , <i>Lactobacillus</i> sp, <i>Klebsiella pneumoniae</i> and <i>Citrobacter freundii</i>
8	C2		$1.9 \times 10^2$						<i>Enterobacter aerogenes</i> and <i>Lactobacillus</i> sp
9	C3		$1.3 \times 10^2$						<i>Enterobacter aerogenes</i> , <i>Lactobacillus</i> sp, <i>Klebsiella pneumoniae</i> and <i>Escherichia coli</i>
10	D1		$1.0 \times 10^3$						<i>Enterobacter aerogenes</i> , <i>Escherichia coli</i> <i>Lactobacillus</i> sp and <i>Pseudomonas aeruginosa</i>
11	D2		$1.9 \times 10^4$						<i>Citrobacter freundii</i> , <i>Enterobacter aerogenes</i> , <i>Escherichia coli</i> , and <i>Pseudomonas aeruginosa</i>
12	D3		$2.0 \times 10^4$						<i>Enterobacter aerogenes</i> , <i>Pseudomonas aeruginosa</i> and <i>Escherichia coli</i>

**Table 2:** Morphological characteristics of bacterial isolates.

Isolate no	Pigmentation/color	Shape	Edge	Optical characteristics	Consistency	Colony surface	Sporulation	Gram's reaction	Motility
------------	--------------------	-------	------	-------------------------	-------------	----------------	-------------	-----------------	----------

1	White	Circular	Entire	Transparent	Butyrous	Smooth	Negative	-ve rod	+
2	White	Irregular	Lobate	Transparent	Viscid	Smooth	Negative	-ve rod	+
3	Milk white	Circular	Entire	Opaque	Butyrous	Smooth	Positive	+ve rod	+
4	Green	Circular	Entire	Transparent	Butyrous	Smooth	Negative	-ve rod	-
5	White	Irregular	Lobate	Transparent	Viscid	Smooth	Negative	-ve rod	+
6	Milk white	Circular	Entire	Opaque	Butyrous	Smooth	Positive	+ve rod	-
7	Milk white	Circular	Entire	Opaque	Butyrous	Smooth	Positive	+ve rod	+

**Table 3:** Biochemical characteristics of bacterial isolates.

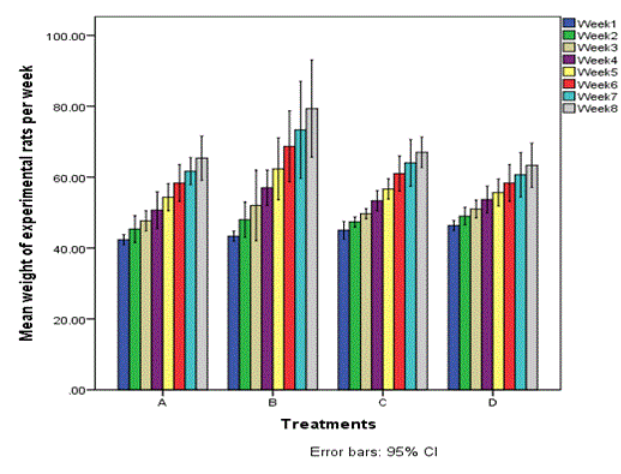
Isolate no	Catalase	Oxidation	Inoculation	H <sub>2</sub> S	Nitrate reductase	Urease	Lactulose	Fructose	Mannitol	Glycerol	Glycerol	Arabinose	Raffinose	Mannose	Mannose	Voges-Proskauer	Indole
1	+	-	+	+	-	+	-	+	-	-	+	-	-	-	+	-	<i>Enterobacter aeruginosa</i>
2	+	-	-	-	-	+	+	+	+	+	+	-	-	+	+	+	<i>Escherichia coli</i>



3	-	-	-	-	+	-	+	+	+	+	+	+	+	+	-	+	+	B ac ill us su bt ili s
4	+	+	-	+	+	-	-	+	+	+	-	+	+	-	+	-	-	Ps eu do m on as ae ru gi no sa
5	+	+	-	+	+	-	-	+	+	+	-	+	+	-	+	-	-	Ci tr ob ac te r fre u nd ii
6	+	-	-	-	+	-	+	+	+	+	-	-	+	+	+	+	Kl eb sie lla p ne u m on ia e	
7	+	+	-	+	+	-	-	+	+	+	-	+	+	-	+	+	L ac to ba cil lu s sp	

The effect of the treatments with orange juice on the weight of the rats showed that the group fed with 0.5 ml of the juice caused the highest weight gain in the rats. However, all the groups fed with the different volumes of the orange juice recorded a higher weight increase than the control group. The group fed with 0.25 ml of the juice daily had an initial weight of  $42.33 \pm 0.58$  g and ended at the eight week with  $65.00 \pm 1.45$  g with significant increase at  $P \leq 0.05$ . Comparatively, the control group started with  $46.33 \pm 0.33$  g and ended at the eight week with  $63.33 \pm 1.45$  g with significant increase at  $P \leq 0.05$ . The

group fed with 0.50 ml of the juice which had the highest impact on the weight started with  $43.33 \pm 0.58$  g and ended at the eight week with  $79.33 \pm 3.18$  g with significant increase at  $P \leq 0.05$ . This result is presented in Figure 3.



**Figure 3:** Effect of the orange juice on the weight of the albino rats per week.

**DISCUSSION**

From the results obtained in this research, the effect of fresh orange juice as a source of vitamins cannot be overemphasized. Although, no comparative study was performed to assess the effect of processed orange juice, it has been known from time immemorial that fresh fruits are more valuable than processed ones [20]. The histopathological results on the vital organs analyzed showed that they are pathologically fine without any degeneration of tissues is an evidence. According to Omoya and Momoh, for an animal to be fed for a period of four (4) weeks constantly on daily basis without pathological deformation of organs such as liver and kidneys is a sign of no toxic content or portion in such substance [14]. The features seen in the kidneys such as mild interstitial mononuclear cell infiltrations, complete tubular generation of Bowman’s capsules, absence of necrosis and glomerular shrinkage are further evidence of the nutraceutical nature of the juice. In simple terms, Pagana puts it as having medicinal values that can boost the fast recuperative nature of injured organs [19].

Furthermore, the presences of features that depict the high biological and metabolic activities of the kidney nephrons were largely seen. There is no form of glomerular basement collapse neither is there any form of glomerular shrinkage of all the kidneys of rats fed with the juice. This result is similar to the result obtained by Berkeley et al. as evidence of active kidney nephron [21]. The fact that no haemorrhage was seen and no collapse of any of the nephrotic vein or renal arteries is a clear indication of the non-toxic nature of the orange juice. In a related study with similar results to corroborate these results, Omoya and Momoh, reported that the first evidence of toxic substances in food for animals is the collapse of renal arteries [14].

There are some of the kidney nephrons with the presence of increased hyaline casts with cell infiltrations. According to Alfaraj, this is a sign of actively multiplying or reproducing

kidney nephrons with the intake of balance diet; especially vitamins in the meal of animals. The few inflammatory cell infiltrations that were common in some of the kidney nephrons are indications that are known only in mature nephrotic areas. This result is corroborated with the results obtained by Adebolu, when she used ogi liquor to feed animals and the kidney nephrons showed inflammatory cells infiltrations [15].

Therefore, since throughout the histopathology of the kidneys of the rats, there was no negative pathology sighted for both the control and in the experimental groups, the orange juices were not in high dosage. However, the group fed with 0.5 ml of the orange juice daily had the best kidney nephron architectural formation. This showed that this volume was the most adequate for the rats based on their weight Adebolu et al. [15].

The results of the histopathology of the liver of the albino rats showed no pathologically deformed features that could be of health concern; rather there were distinct and well-formed hepatocytes. This is usually rare according to Alfaraj because even most foods and food substances are toxic to the liver; especially when taken in excess. Since there was no hepatocellular drainage or carbuncle, then the juice are relatively safe and the quantity administered adequate. According to Adebolu et al., this may be due to the nature of oranges which are rich in vitamin C [15]. Vitamin C on the other hand are water soluble and excess of it are often passed out in urine thereby preventing any damage it could have caused the body as emphasized in Stedman's medical dictionary.

Cuttings differ in saying that although, excess of vitamin C may not harm the body, the effect will always be seen in organs that it has to pass through during ultrafiltration's and circulation. These organs include the kidneys, liver and sometimes the heart. According to Baker et al., since there is no wide spread of vascular damage of hepatocytes or blood arteries and veins seen, the feed alongside the orange juice (substance of treatment in this research) has therapeutic value [16]. The aggregation of lymphatic cells which were adequately closed and the separation of sinusoids were signs that the liver hepatocytes are actively involved in metabolic activities of detoxification.

Equally, the fact that no necrosis or necrotic apoptosis was seen and hemorrhage was not traced along any of the blood vessels showed that no toxic substances ingested as that would have led to hepatocellular karyolysis and anterior or posterior or both showing degeneration. No cellular degeneration of hepatocytes and micro-vesicular fatty infiltrations. The fatty cyst formation of the hepatocytes are adequate with the portal and central venous not congested. In all the liver hepatocytes analysed, no inflammatory cell infiltrations and no disappearing sinusoids due to karyolysis of any form. All these features according to Stedman's medical dictionary can only be when essential vitamins are adequately supplied. This was in contrast with the hepatocytes of the control groups that showed tendency to be more rigid with distinct formation which according to Akparie is an indication of lack of some essential vitamins and organo-sinusoidal scurvy of the liver hepatocytes.

The results obtained for the effects of the treatments on the haematological indices of the rats assayed for has shown that

orange juice can help to increase blood volume of animals when taken constantly. However, from the results, it could be seen that as the volume of the juice given daily increases, the blood volume also increases. Hence, the group given 1 ml of orange juice had an average PCV of  $51.22 \pm 1.24\%$  which is almost more than 10% volume than the blood PCV of the control group which was  $41.33 \pm 0.67\%$ . This couldn't have been a coincidence. According to Crowell and Tsuda et al., orange juice can improve blood quality and prevent cancer [11,22]. In a related study by Cha et al., fresh orange juice can cause an increase in blood volume and neutralize orotic acid in the blood [23]. According to Mosele et al., orange juice has a purifying strength on blood which frees the blood from impurity that could obstruct the free flow of blood through the heart and blood vessels thereby giving the chance to the blood to increase [24]. This purifying ability consequently helps the blood overcome infection and prevent infection thereby endowing orange juice with therapeutic properties.

The ability of orange juice to prevent diseases by purifying the blood stream and the blood vessels may be responsible for the low value of lymphocytes and monocytes in the white blood cell differential count analysis. This is evident in the values obtained for the results in which there was no significant differences at  $P \leq 0.05$  in the values obtained for the two parameters between the experimental and the control group. There was also no significant differences at  $P \leq 0.05$  in the values obtained for the control and experimental groups for eosinophils and basophils. This result is expected as according to Stedman's dictionary, significant differences in these values can only occur when or if there is parasitic infection and hypersensitivity reaction in the experimental animals.

The effect of the orange juice treatment on the guts of the animals can best be described as salient. The bacteria load as seen in Table 1 was reducing as the volume of the orange juice given was increasing. According to Prescott et al., any food or drink capable of reducing the bacteria load of the gut, especially eliminating pathogenic gut flora will have therapeutic or medicinal value [25]. One common trend on the results obtained in the identity of the isolates in Table 1 is that there is significant reduction in the bacteria load of the rats as the volume of the juice increases. Also worthy of note is in the types of bacteria identified from the gut of the animals. Bacteria like *Pseudomonas aeruginosa* was gradually eliminated from the gut flora as the volume of juice increases while *Lactobacillus* sp was gradually introduced. This bacteria which is a probiotic probably was introduced into the animals by the juice. According to Oyetayo however, stated that *Lactobacillus* sp will always be present in the gut of animals but may be suppressed by the other gut microflora based on the diet of the animal which may support the growth of other gut flora.

In a related research by Davila et al., citrus fruit, especially fresh orange juice contain some active biological antioxidants and antibacterial components that is able to get rid of some of the enteric bacteria that are yet colonize the gut properly [26]. According to Omoya and Momoh, orange juice can increase the rate of proliferation of *Lactobacillus* sp *in vivo* when tested on rabbits and guinea pigs [14]. All the bacteria isolated from the

gut are all enteric bacteria. According to Brooks et al., the seven (7) bacteria were isolated and identified using standard microbiological procedures are all *enterobacteriaceae* with the exception of *Lactobacillus* sp and *Bacillus cereus* [27]. These bacteria are *Enterobacter aerogenes*, *Escherichia coli*, *Bacillus cereus*, *Klebsiella pneumonia*, *Citrobacter freundii*, *Lactobacillus* sp and *Pseudomonas aeruginosa*.

According to Prescott et al., *Enterobacter aerogenes* and *Escherichia coli* are *enterobacteriaceae* that are classified as faecal coliforms because they are always present in the faeces of mammals [25]. Likewise, the presence of *Klebsiella pneumonia* and *Citrobacter freundii*. Therefore, their presence may have being from the fact that they are normal flora of the gut. The presence of *Bacillus* on the other hand may be from the soil or foods picked from the floor by the animals. These animals do not have special hands like man with which to handle their food. *Lactobacillus* is a genus of Gram-positive, facultative anaerobic or microaerophilic, rod-shaped, non-spore-forming bacteria Makarova et al. *Lactobacillus* species are normally a major part of the vaginal microbiota. They form biofilms in the vaginal and gut microbiota, allowing them to persist during harsh environmental conditions and maintain ample populations [28]. *Lactobacillus* exhibits a mutualistic relationship with the human body as it protects the host against potential invasions by pathogens, and in turn, the host provides a source of nutrients Martin et al. Some species commonly used in yogurt production includes; *L. bulgaricus*, *L. acidophilus*, *L. casei*, *L. animalis*. Therefore, orange juice could support their proliferation in the gut and some may have even entered through the juice fed to the rats [29,30].

The effect of the treatments with orange juice on the weight of the rats which showed that the group fed with 0.5 ml of the juice caused the highest weight gain in the rats has proof beyond reasonable doubt that orange juices were very medicinal. However, all the groups fed with the different volumes of the orange juice recorded a higher weight increase than the control group. The group fed with 0.25 ml of the juice daily had an initial weight of  $42.33 \pm 0.58$  g and ended at the eight week with  $65.00 \pm 1.45$  g with significant increase at  $P \leq 0.05$ . Comparatively, the control group started with  $46.33 \pm 0.33$  g and ended at the eight week with  $63.33 \pm 1.45$  g with significant increase at  $P \leq 0.05$ . The group fed with 0.50 ml of the juice which had the highest impact on the weight started with  $43.33 \pm 0.58$  g and ended at the eight week with  $79.33 \pm 3.18$  g with significant increase at  $P \leq 0.05$ . These results corroborate the effectiveness of the orange juice as antibacterial and effective for man animals respectively [30-50].

From the results obtained in this research, orange juice is a good immunity booster, aid proliferation of normal microbiota of the guts, help with introduction and increase presence of probiotics as well as increase in the weight of animals when taken constantly on regular basis. Therefore, constant consumption of orange juice on a regular basis is highly recommended.

The results obtained in this research has proof the effect of fresh orange juice as a source of vitamins which cannot be overemphasized. The histopathological results on the vital organs analyzed showed that they are pathologically fine without any degeneration of tissues thereby providing an evidence that

fresh orange juice has prophylactic and therapeutic values; since they were fed to animals for a period of more than four weeks which is the maximum duration a substance fed to animals takes to deform the vital organs directly involved in the metabolic processes of such substance. In simple terms, fresh orange juice have medicinal values that can boost immunity and cause significantly fast recuperation of injured organs. It can help to increase blood volume of animals when taken constantly as well as restore normal gastrointestinal microflora as seen in this research.

## CONCLUSION

Therefore, regular intake of fresh orange juice is recommended for immunity boost, restoration of normal gastrointestinal microflora, weight increase and efficiently healthy working vital organs such as kidney and liver.

## ACKNOWLEDGMENTS

The authors are grateful to Elizade University management and the technologists of Biological Sciences department of Elizade University. Our gratitude also goes to Obafemi Awolowo University animal's house staff including their veterinary doctors that ascertain the health status of the rats. The research was financially supported by Mr. Loyibo who single-handedly provided for the research.

## CONFLICT OF INTEREST

The authors declare that there is no conflict of interest that could be perceived as prejudicing the impartiality of the research reported.

## ETHICS STATEMENT

This study received approval from both the welfare committee of animal experimentation of the Federal University of Technology, Akure (2019/02/PID068) and the Animal Use and Care Committee (AUCC) of the National Veterinary Research Institute, Vom, Nigeria with Project No. ID 169.

## AUTHOR CONTRIBUTIONS

Momoh O. Abdul developed the original idea and the protocol, abstracted and analyzed data, wrote the manuscript, and is the guarantor. Loyibo E. contributed to the development of the protocol, financed the project, execution of the project and participated in the preparation of the manuscript.

## REFERENCES

1. Sissay MT, Lise-Korsten C. *Citrus sinensis* disease survey: knowledge, attitude and management practices in Ethiopia. Trop Res J. 2006;4:1-9.
2. Piccinelli AL, García MM, Armenteros DM, Alfonso MA, Arevalo AC, Campone L, et al. HPLC-PDA-MS and NMR Characterization of C-Glycosyl Flavones in a Hydroalcoholic Extract of *Citrus aurantifolia* Leaves with Antiplatelet Activity. J Agric Food Chem. 2008;56(5): 1574-1581.
3. Angew ON. Functional foods. Trends Food Sci Technol. 2007;30:19-21.

4. Bernardi J, Licciardello C, Russo MP, Luisa CM, Carletti G, Recupero GR, et al. Use of a custom array to study differentially expressed genes during blood orange (*Citrus sinensis* L. Osbeck) ripening. *J Plant Physiol.* 2010;167:301-310.
5. Xu Q, Chen LL, Ruan X, Chen D, Zhu A, Chen C, et al. The draft genome of sweet orange (*Citrus sinensis*). *Natur Genet.* 2013;45(1):59-68.
6. Guarner F, Malagelada JR. Gut flora in health and disease. *Lancet.* 2003;361:512-519.
7. Hattori M, Taylor TD. The human intestinal microbiome: A new frontier of a human biology. *DNA Res.* 2009;1:1-12.
8. Sliwska K, Klewicka E, Motyl I. Mikroflora człowieka. In: *Mikrobiologia Techniczna. Mikroorganizmy i rodowiska ich występowania.* Red. Libudzisz Z., Kowal K., akowska Z. PWN, Warszawa. 2008;pp:240-248.
9. Libudzisz Z, Nowak A. Human intestinal microorganisms. *Medical Standards.* 2008;2:372-379.
10. Tripoli E, La-Guardia M, Giammanco S, Di-Majo D, Giammanco M. Citrus flavonoids: Molecular structure, biological activity and nutritional properties: A review. *Food Chem.* 2007;104:466-479.
11. Crowell PL. Prevention and therapy of cancer by dietary monoterpenes. *J Nutr.* 2010;129(3):775-778.
12. Di-Majo D, Giammanco M, La-Guardia M, Tripoli E, Giammanco S, Finotti E. Flavanones in Citrus fruit: Structure antioxidant activity relationships, *Food Res Intern.* 2005;38:1161-1166.
13. Ejaz S, Ejaz A, Matsuda K, Chae WL. Limonoids as cancer chemopreventive agents. *J Sci Food Agric.* 2006;86:339-345.
14. Omoya FO, Momoh AO. Comparative effects of garlic, yoghurt, beniseed liquor and fresh orange juice on induced type-1 diabetes mellitus in rabbits using streptozotocin. *J Food Nutr Disor.* 2019;8(4):1-9.
15. Ehler SA. Citrus and its benefits. *J Botany.* 2011;5:201-207.
16. Baker FJ, Breach MR, Chris P. *Medical laboratory Science.* Chris Publisher, London. 2016;pp:487.
17. Cheesebrough M. *District Laboratory Practice in Tropical Countries.* Low price (2nd edition) update. Cambridge University Press, United Kingdom. 2014;pp:588.
18. Clemente JC, Ursell LK, Parfrey LW, Knight R. The impact of the gut microbiota on human health: An integrative view. *Cell.* 2012;148:1258-1270.
19. Pazirandeh S, Burns DL. Overview of water-soluble vitamins. 2017.
20. Aschoff JK, Kaufmann S, Kalkan O, Neidhart S, Carle R, Schweiggert RM. In Vitro Bioaccessibility of Carotenoids, Flavonoids, and Vitamin C from Differently Processed Oranges and Orange Juices [*Citrus sinensis* (L.) Osbeck]. *J Agricul Food Chem.* 2015;63(2):578-587.
21. Berkeley DSB, Kizar K, Radha S. *Gymnema Sylvestre* for Diabetes. *J Ethnopharmacol.* 2016;30:295-300.
22. Tsuda H, Ohshima Y, Nomoto H, Fujita KI, Matsuda E, Iigo M, et al. Cancer prevention by natural compounds. *Drug Metabol Pharmacokin.* 2014;19(44):245-263.
23. Cha JY, Cho YS, Kim I, Anno T, Rahman SM, Yanagita T. Effect of hesperetin, a citrus flavonoid on the liver triacylglycerol content and phosphatidate phosphohydrolase activity in orotic acid-fed rats. *Plant Foods Human Nutr.* 2015;56:349-358.
24. Mosele JI, Gosalbes MJ, Macià A, Rubió L, Vázquez-Castellanos JF, Jiménez-Hernández N, et al. Effect of daily intake of pomegranate juice on fecal microbiota and feces metabolites from healthy volunteers. *Molec Nutr Food Res.* 2015;59(10):1942-1953.
25. Prescott LM, Harley JP, Klein DA, Adidias J. *General Microbiology,* 10th Edition McGraw Hill, New York. 2018.
26. Davila AM, Blachier F, Gotteland M, Andriamihaja M, Benetti PH, Sanz Y, et al. Intestinal luminal nitrogen metabolism: Role of the gut microbiota and consequences for the host. *Pharmacol Res.* 2013;68:95-107.
27. Brook GF, Butel JS, Morse SA. *Medical Microbiology* (27th edition). McGraw Hill, New York. 2017;pp:850.
28. Arora DR, Brij BA. *Text Book of Microbiology;* CBS Publishers and distributors, India. 2016;pp:1-696.
29. Bai J, Baldwin EB, Hearn J, Driggers R, Stover E. Volatile Profile Comparison of USDA Sweet Orange-like Hybrids versus 'Hamlin' and 'Ambersweet'. *Hort Science.* 2014;49(10):1262-1267.
30. Dueñas M, Muñoz-González I, Cueva C, Jiménez-Girón A, Sánchez-Patán F, Santos-Buelga C, et al. A survey of modulation of gut microbiota by dietary polyphenols. *BioMed Res Intern.* 2015;pp:1-15.
31. Faturi CB, Leite JR, Alves PB, Canton AC, Teixeira-Silva F. Progress in neuro-psychopharmacology and biological psychiatry. Epub. 2010;pp:15-19.
32. Frick JS, Autenrieth IB. The gut microflora and its variety of roles in health and disease. *Curr Topic Microbiol Immunol.* 2013;358:273-289.
33. Gerritsen J, Smidt H, Rijkers GT, De-Vos WM. Intestinal microbiota in human health and disease: The impact of probiotics. *Genes Nutr.* 2011;6:209-240.
34. Honow R, Laube N, Schneider A, Kessler T, Hesse A. Influence of grapefruit, orange, and apple-juice consumption on urinary variables and risk of crystallization. *British J Nutr.* 2003;90:295-300.
35. Kurowska EM, Manthey JA. Hypolipidemic effects and absorption of citrus polymethoxylated flavones in hamsters with diet-induced hypercholesterolemia. *J Agric Food Chem.* 2004;19:2879-2886.
36. Manthey JA, Guthrie N, Grohmann K. Biological properties of citrus flavonoids pertaining to cancer and inflammation. *Curr Med Chem.* 2001;8:135-153.
37. Morton J. Orange, *Citrus sinensis.* In: *Fruits of Warm Climates.* New CROP, New Crop Resource Online Program, Center for New Crops and Plant Products, Purdue University. 2010;pp:134-142.
38. Nguendo-Tongsi HB. Microbiological evaluation of drinking water in a sub-saharan urban community (Yaounde). *American J Biochem Molec Biol.* 2011;1:68-81.
39. Nwidi LL, Oveh B, Okoriye T, Vaikosen NA. Assessment of the water quality and prevalence of water borne diseases in Amassoma, Niger Delta, Nigeria. *African J Biotechnol.* 2018;7(17):2993-2997.
40. Parmar HS, Kar A. Medicinal values of fruit peels from *Citrus sinensis*, *Punica granatum* and *Musa paradisiacal* with respect to alterations in tissue lipid peroxidation and serum concentration of glucose, insulin and thyroid hormones. *J Med Food.* 2008;11:376-381.
41. Pereira-Caro G, Borges G, Ky I, Ribas A, Calani L, Del-Rio D, et al. In vitro colonic catabolism of orange juice (poly)phenols. *Molec Nutr Food Res.* 2015;59(3):465-475.
42. Sekirov I, Russell SL, Antunes LCM, Finlay BB. Gut microbiota in health and disease. *Physiological Reviews.* 2010;90:859-904.
43. Sharma N, Tripathi A. Effects of *Citrus sinensis* (L.) Osbeck epicarp essential oil on growth and morphogenesis of *Aspergillus niger* (L.). *Microbiol Res.* 2008;163:337-344.
44. Simon JA, Hudes ES, Perez-Perez GI. Relation of serum ascorbic acid to *Helicobacter pylori* serology in US adults: The Third National Health and Nutrition Examination Survey. *J American Col Nutr.* 2003;22:283-289.
45. Strange RR, Miland SL, Eckert JW, Sims JJ. An antifungal compound produced by grapefruit and valencia orange after wounding of the peel. *J Nat Prod.* 1993;56:1627-1629.
46. Tanaka Y, Makita H, Kawabata K, Mori H, Kakumoto M, Satoh K, et al. Modulation of N-methyl-N-nitrosamine-induced rat oesophageal tumorigenesis by dietary feeding of diosmin and hesperidin, both alone and in combination. *Carcinog Agric Food Chem.* 2007;18:761-769.



47. Vivek KR, Nandini SS, Anitha S. Anti-typhoid activity of aqueous extract of fruit peel *Citrus sinensis*. Intern J Pharmaceut Res Develop. 2010;2:217-219.
48. Wiesman Z, Chapagain BP. Larvicidal of aqueous extracts of *Balanites aegyptiaca* (desert date) against the larvae of *Culex pipiens* mosquitoes. African Biotechnol. 2005;4:1351-1354.
49. World Health Organization (WHO). Iron in Drinking Water. Background document for Drinking Water Quality. Geneva, World Health Organization. 2013.
50. World Health Organization (WHO). Guidelines for drinking water quality. Third Edition, WHO press, Geneva, Switzerland. 2016;pp: 398.